

# Efficacy of 3-Snip Posterior Rectangular Punctoplasty in the Treatment of Acquired External Punctal Stenosis

IFTIKHAR AHMED<sup>1</sup>, WAQAR AHMED<sup>2</sup>, MUNIR AHMED<sup>3</sup>

## ABSTRACT

**Purpose:** To assess the efficacy of 3-snip posterior punctoplasty in the treatment of acquired external punctal stenosis.

**Study design:** A retrospective non-comparative interventional study.

**Methods:** Fifty two (52) eyes of forty one (41) patients with symptoms of acquired external punctal stenosis underwent conventional 3-snip posterior rectangular punctoplasty as an outdoor procedure by a single surgeon. Detailed history was taken and subjective grading of epiphora was done by Munk scale. The size of punctum and tear meniscus height was determined on slit lamp examination. Dye disappearance test, tear film breakup time and diagnostic probing and irrigation were performed on each patient before operation.

**Results:** The age ranged between 21 and 88 years (mean, 63.7 years). Twenty seven patients (65.85%) were females and fourteen (34.15%) males. There was a definite increase in tendency with advancing age. The subjective epiphora score and preoperative tear meniscus height were significantly reduced. The grade of punctum size was increased after the surgery and the enlargement was maintained till 8 months postoperatively. The dye disappearance test (DDT) and tear meniscus height also became normal and remained so throughout the postoperative observation period. The success was defined as a subjective improvement in the symptoms. Functional success rate was 80.76% (42 eyes) and anatomical success rate 90.38% (47 eyes). The procedure failed only in 9.62% (5 eyes).

**Conclusion:** The success rate in the review confirms that 3-snip posterior punctoplasty is the most logical and reliable procedure in the treatment of acquired external punctal stenosis (AEPS).

**Keywords:** Epiphora, punctal stenosis, posterior punctoplasty.

---

## INTRODUCTION

The lacrimal drainage system begins at the superior and inferior puncta located medially in both the upper and lower eyelid margins. The lacrimal puncta are components of tarsal plates in both the eyelids<sup>1</sup>. The upper punctum is 6mm and the lower 6.5mm from the medial canthus<sup>2</sup>. The external lacrimal puncta are approximately 0.3 mm in diameter<sup>3</sup>. There is no commonly agreed definition of punctal stenosis, however progressive constriction of puncta which prevents normal drainage of tears leading to epiphora is called punctal stenosis<sup>4</sup>. The simple clinical test to diagnose punctal stenosis is, whether or not the undilated punctum would admit a 26 G lacrimal canula. If the punctum does not admit the canula without prior dilatation, it is classified as stenosed<sup>5</sup>. There is a proposed grading system for the assessment of pre and postoperative state of

external punctal stenosis (grade 0-2) and slit punctum (grade 4-5) based on slit lamp examination and the way to enter a #00 Bowman probe<sup>6</sup> (Table 1) (Fig 1).

The common causes of punctal stenosis are idiopathic, primary age related, chronic infections and inflammatory eyelid disorders, cicatricial scarring, trauma, chemical and thermal burns, irradiation, prolonged use of antiglaucoma and antiviral drops and topical and systemic antineoplastic drugs<sup>7</sup>.

The basic principle in the treatment of punctal stenosis is to create an adequate opening, while maintaining the position of the punctum in the tear lake and preserving the lacrimal pump function<sup>8,9</sup>. The surgery of choice is punctoplasty. Assuming that rest of the system is patent, the procedure establishes normal tear drainage<sup>10</sup>. Different methods of punctoplasty have been tried to augment the size of the punctum including 3-snip rectangular posterior punctoplasty<sup>11</sup>. It is a conservative method in which two vertical and a horizontal cut is made to create a rectangular defect in the posterior wall of the ampulla.

<sup>1</sup>Assistant Professor Ophthalmology Continental Medical College, Township, Lahore

<sup>2</sup>Dept. of Ophthalmology, Lahore General Hospital, Lahore

<sup>3</sup>Assistant Professor of Ophthalmology, Akhtar Saeed Medical & Dental College, Lahore

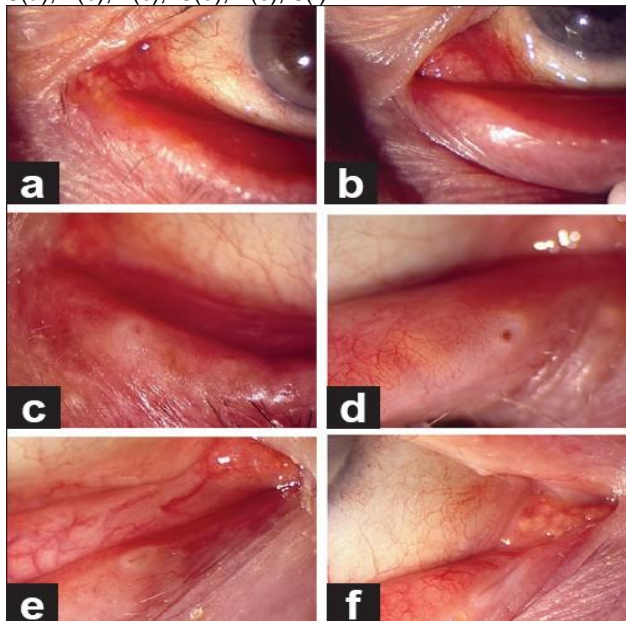
Correspondence to Dr. Iftikhar Ahmed, Assistant Professor

**MATERIAL AND METHODS**

Fifty two (52) eyes of forty one (41) patients with symptoms of acquired external punctal stenosis were selected from eye OPD for study. All underwent conventional 3-snip posterior rectangular punctoplasty by a single surgeon. The study was carried out at Ch. Rehmat Ali Memorial Trust Hospital, Continental Medical College, Lahore from April, 2008 to May, 2011. A detailed history of any systemic or topical medication, surgery, and trauma or lid infection was taken and subjective grading of Epiphora (0-5) was done (Table 5) by Munk scale<sup>2</sup> (Table 2). All underwent slit lamp examination to evaluate and grade the size of punctum (0-5) (Table 4) using the criteria used by Kashkouli et al<sup>6</sup>. The tear meniscus height was then measured using a slit lamp biomicroscope. A level >2mm was considered significant. Eyelid distraction test<sup>13</sup> was done to determine the lid laxity and health of lacrimal pump. Dye disappearance test (DDT), tear film breakup time (BUT), diagnostic punctum dilatation test and irrigation of the lacrimal passage were performed on each patient before the surgery.

Patients with epiphora grading 3-5, lacrimal punctum grade 1 & 2, a tear meniscus height >2 mm, normal punctum dilatation and nasolacrimal passage irrigation test were included, Whereas the patients with history of previous surgery on nasolacrimal passage, inflammatory and involuntional eyelid diseases, punctum grades 0,3,4,5, positive tear film breakup time and those who did not report for follow up were excluded from the study.

Figure 1: External lacrimal punctal grading<sup>6</sup>. 0(a), 1(b), 2(c), 3(d), 4(e), 5(f)



The surgery was accomplished by injecting 0.5 cc of 2% lignocaine with 1:10,000 epinephrine subcutaneously below the lower punctum and instillation of 1% Alcaine eye drops 3 to 4 times after every 5 minutes. The punctum was found with a punctum seeker and dilated sufficiently. The posterior wall of the ampulla was firmly grasped with micro forceps and with the help of vanna's scissors two downward snips on each side of the forceps and a third on the bottom was made to create a rectangular defect. Antibiotic eye drops 4 times a day were prescribed and the patients were reviewed after 1 week, 1 month and 8 months. SPSS 14 was used to analyze the data. Frequencies and percentages were used to describe the data. The level of significance was set at p<0.05.

Table 1: Grading of external lacrimal punctum<sup>6</sup>

Grade	Clinical findings on slit lamp examination; Insertion method for a #00Bowman probe
0	No papilla & punctum (punctal atresia); surgery to create a papilla
1	Papilla is covered by a membrane; a#25needle, followed by a punctal finder. Exudative or true membrane or fibrosis, difficult to recognize with standard dilator
2	Less than normal size, but recognizable; a punctum finder and then a standard punctum dilator required
3	Normal; regular punctum dilator required
4	Small slit (<2mm); no intervention required
5	Large slit (>2mm); no intervention required

Table 2: Munk Scale for epiphora grading<sup>2</sup>

Grade	Munk scale
0	No epiphora
1	Epiphora requiring dabbing <twice a day
2	Epiphora requiring dabbing 2-4 times a day
3	Epiphora requiring dabbing 5-10 times a day
4	Epiphora requiring dabbing >10 times a day
5	Constant Epiphora

**RESULTS**

The age ranged between 21 and 88 years (mean 63.7 years). Twenty seven patients (65.85%) were females and fourteen (34.15%) males. There was a definite increase in tendency of the disease with advancing age. The post-operative subjective Epiphora score was improved (Table 5) and the grade of punctum size was enlarged in significant number of cases (Table 4) at 1st postoperative check-up and was maintained till 8 months post-operatively. The dye disappearance test and pre-operative tear meniscus height also became normal in 80.76% (42 eyes) and remained so throughout the post-operative observation period.

The functional success rate in terms of subjective improvement of symptoms was 80.76% (42 eyes) whereas anatomical or surgical success rate which is restoration of normal size of puncta with or without improvement in subjective symptoms was 90.38% (47 eyes)(Table 6). The procedure failed only in 9.62% (5 eyes) (Fig.2) due to healing of the cut edges of the punctoplasty. The success rate in our study is comparable to 77.4% complete functional success and 98.2% anatomical success in a study carried out by Kashkouli et al<sup>14</sup> and 92% success rate in the study carried out by Caesar et al<sup>5</sup>.

Fig. 2: Showing success and failure rates

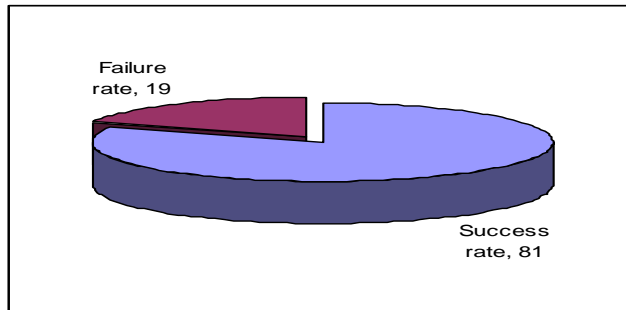


Table 3: Patients data (n= 41)

Age		21-88 Years
Gender	Male	14(34.14%)
	Female	27(65.85 %)
Laterality	Unilateral	30(73.17%)
	Bilateral	11(26.83%)

Table 4: Pre and Post-Operative Punctum grades

Pre or Post-Operative	No. of eyes	Punctum grade	n(%)
Pre-Operative	19	1	36.53
	33	2	63.46
Post operative	21	3	40.38
	26	4	50
	3	1	5.77
	2	0	3.84

Table 5 :Pre and Post-operative Epiphora grade

Pre or Post-Operative	No. of eyes	Epiphora grade	n(%)
Pre-Operative	18	3	34.61
	20	5	38.46
	14	4	26.92
Post operative	35	0	67.30
	4	1	7.69
	3	2	5.76
	3	3	5.76
	5	4	9.62
	2	5	3.84

Table 6: Success rate n(%)

Total eyes	Follow up period	Success rate
52	8 months	Functional success (80.76%)
52	8 months	Surgical or anatomical success (90.38%)

## DISCUSSION

Punctal stenosis is a common finding among patients presenting for routine eye check-up. It increases with advancing age<sup>7,15</sup> a little more common in females and the most common predisposing factor is chronic blephritis. Different surgical procedures including 1, 2 and 3-snip punctoplasty, 1 snip punctoplasty with mini Monoka tube insertion, posterior punctectomy with intraoperative Mitomycin( MMC), punch punctoplasty, laser punctoplasty and punctum pucker procedure have been done to augment the size of punctum by different surgeons. The 3-snip posterior punctoplasty is a straight forward procedure indicated in the treatment of symptomatic acquired external punctal stenosis<sup>5</sup>, patent to syringing once the punctum is dilated. The procedure was refined in to modern 3-snip by Thomas in 1951<sup>16</sup> and Viers<sup>17</sup> in 1955 after Graves<sup>18</sup> who described his posterior ampullectomy. The anatomical principle of punctoplasty is to enlarge permanently a stenosed punctum, bring the enlarged punctum closer to tear meniscus and preserve the canaliculus. By basic surgical principles, it is clear that the posterior wall of the ampulla needs to be excised to achieve these aims. By using three snips, the raw edges are not in contact and should not heal and re-stenose the punctum.

## CONCLUSION

80.76% functional success rate in the review confirms that 3- snip posterior punctoplasty is an anatomically and surgically logical and reliable procedure in the treatment of acquired external punctal stenosis. It is also a safe, simple, quick and economical procedure which not only makes the proximal lacrimal passage patent but also preserves the lacrimal pump action.

## REFERENCES

1. Takahashi Y, Kakizak H, Nakano T, Asamoto K, Ichinose A, Iwaki M. Anatomy of the vertical lacrimal canaliculus and lacrimal punctum: A macroscopic study. *Ophthal Plast Reconstr Surg.* 2011;27:384–6.
2. Basic and Clinical course. Section 2, Fundamentals and Principles of Ophthalmology. American Academy of Ophthalmology. 2008-2009:36.

3. Hirschbein MJ, Stasior GO. In: Oculoplastic surgery, the Essentials. 1st ed. New York: Theime; 2001. Lacrimal System; pp. 263–4.
4. Kashkouli MB, Beigi B, Murthy R, Astbury N. Acquired external punctal stenosis: Etiology and associated findings. *Am J Ophthalmol.* 2003;136:1079–84.[PubMed]
5. Caesar RH, McNab AA. A brief history of punctoplasty: the 3-snip revisited. *Eye* 2005;19:16-18
6. Kashkouli MB, Nilfroushan N, Nojomi M, Rezaee R. External lacrimal punctum grading: Reliability and interobserver variation. *Eur J Ophthalmol.* 2008;18:507–11.[PubMed]
7. Kashkouli MB, Beigi B, Murthy R, Astbury N. Acquired external punctal stenosis, etiology and associated findings. *Am J Ophthalmology* 2003;136(6):1079-1089
8. Ma'luf RN, Hamush NG, Awwad ST, Nouredin B. Mitomycin C as adjunct therapy in correcting punctal stenosis. *Ophthal Plast Reconstr Surg.* 2002;18:285–8.
9. Konuk O, Urgancioglu B, Unal M. Long-term success rate of perforated punctal plugs in the management of acquired punctal stenosis. *Ophthal Plast Reconstr Surg.* 2008;24:399–402.
10. Alan Ng, Dylan Chan. Management of tearing in adults. *Medical bulletin:Nov.2007;12(9):05*
11. Chak M, Irvine F. Rectangular 3-snip Punctoplasty Outcomes: Preservation of the lacrimal pump in punctoplasty surgery. *Ophthal Plast Reconstr Surg.* 2009;25:134–5.
12. Munk PL, Lin DT, Morris DC. Epiphora: Treatment by means of dacryocystoplasty with balloon dilation of the nasolacrimal drainage apparatus. *Radiology.* 1990;177:687–90.[PubMed]
13. Narayanan K, Barnes EA. Epiphora with eyelid laxity. *Orbit.* 2005;24:201–3.[PubMed]
14. Kashkouli MB, Beigi B, Austbury N. Acquired external punctal stenosis: Surgical management and long term follow-up. *Orbit.* 2005;Jun24(2)73-8
15. Kristan R. Branch treatment of lacrimal punctal stenosis with a 1-snip canaliculectomy and temporary punctal plug. *Arch Ophthalmol.* 1888;106:878-9{PubMed}.
16. Thomas JBT. A modification of Graves' operation for epiphora due to stenosis of the lacrimal punctum. *Br J Ophthalmol* 1951; **35**: 306. | PubMed | ChemPort
17. Viers ER. Disorders of the canaliculus. In: *The Lacrimal System* Grune & Stratton: New York 1955; pp 46–47.
18. Graves B. Making a new lacrimal punctum. *Am J Ophthalmol* 1926; **9**: 675–677.